

# Brain mapping in animals and humans

Martin I Sereno

Studies using functional magnetic resonance imaging (fMRI) to map cortical areas in humans have revealed many similarities with recent cortical mapping studies from nonhuman primates as well as some striking differences. Improved methods for analyzing, displaying and averaging fMRI data on an unfolded cortical surface atlas are poised to improve the integration of information across burgeoning numbers of imaging studies. By combining fMRI with electrical and passive magnetic imaging modalities, the millisecond-to-millisecond sequence of activation of different cortical regions elicited by an event can be imaged, provided the regions are sufficiently far apart.

## Addresses

Cognitive Science 0515, University of California at San Diego, La Jolla, California 92093-0515, USA; e-mail: sereno@cogsci.ucsd.edu; URL: <http://cogsci.ucsd.edu/~sereno/>

**Current Opinion in Neurobiology** 1998, **8**:188–194

<http://biomednet.com/elecref/0959438800800188>

© Current Biology Ltd ISSN 0959-4388

## Abbreviations

<b>DI</b>	dorsointermediate area
<b>DL</b>	dorsolateral area
<b>DM</b>	dorsomedial area
<b>EEG</b>	electroencephalography
<b>fMRI</b>	functional magnetic resonance imaging
<b>MEG</b>	magnetoencephalography
<b>MT</b>	middle temporal area
<b>V1</b>	primary visual cortex
<b>V3</b>	third visual area (or V3d)
<b>V3A</b>	V3 accessory area
<b>V4v</b>	ventral V4 (or VA)
<b>VP</b>	ventroposterior area (or V3v)

## Introduction

### Why a comparative approach is important

Detailed, invasive anatomical and physiological experiments can routinely be carried out only in nonhuman (and non-ape) primates—mainly New and Old World monkeys, and lorises (e.g. the galago). The macaque monkey is a natural choice as a ‘model system’ for humans because Old World monkeys are the primate group most closely related to humans (apart from gibbons and great apes). However, the last common ancestor of humans and macaques dates to perhaps 30 million years ago [1]. Since that time, the macaque brain has evolved independently from the brains of apes and humans. Some of the differences between macaque and human brains are the result of specializations peculiar to Old World monkeys (these are the ‘shared derived characters’ that evolutionary biologists prize most highly for the purpose of determining evolutionary branching patterns). One key method for separating these unique specializations from

features likely to be common to humans and macaques is to examine other primate groups; this provides a more principled basis for extending the results of invasive animal experiments to humans [2–4].

### Solving the (cortical) folding problem

Much of the primate brain is composed of thick, two-dimensional (2D) sheets of neurons that project in a topographic fashion to other 2D sheets. As the brain has expanded, these 2D sheets (e.g. the neocortex) have typically been thrown into folds so that their larger surface areas would fit into a reasonable volume (as the volume of a growing sphere increases much more rapidly than its surface area). A similar process has taken place in many brain regions—for example, the deep cerebellar dentate nucleus and the inferior olive each form miniature convoluted ‘cortices’ of their own in humans. This mundane consequence of scaling greatly complicates the task of mapping structural and functional regions in the large human brain. Recent advances in automating surface reconstruction and unfolding, however, have the potential to make surface representations as common in human imaging studies as they have been in studies of nonhuman primates.

In this review, progress in mapping the brains of monkeys and humans in the past year is first described with a focus on visual cortical areas (see also [5,6]). Second, prospects for more user-friendly data display, and more precise between-subject alignment are discussed. Third, efforts to improve temporal resolution by combining multiple imaging modalities are assessed.

## Mapping visual areas in nonhuman and human primates

### Defining visual areas

Visual cortical areas in monkeys are typically small, irregularly shaped, and somewhat variable in location. It is usually difficult to mark their borders on anatomical grounds alone. One method for distinguishing visual areas relies on the fact that many are retinotopically organized to some degree [7–9]. Given a dense cortical map of receptive field eccentricity and polar angle, it is possible to calculate whether each small patch of the cortex represents the visual field as a mirror image (such as V1, the primary visual area) or a non-mirror-image (such as V2, the second visual area). As a locally defined measure, ‘visual field sign’ can be used as another ‘stain’ to divide up the cortex. This technique was originally developed to mark the borders of different visual areas within large retinotopic mapping data sets from monkeys [10]. By combining stimuli that encode eccentricity (or polar angle) during the phase of a periodic response [11] with explicit reconstruction and unfolding of the cortical surface [12], it has become possible to

apply the field-sign technique to human subjects [13]. These and related methods have opened the way to detailed comparisons between visual areas in monkeys and in humans [14,15,16•,17••]. This work has revealed similarities, but also some striking differences, in the organization of human and monkey visual areas.

#### **Striate cortex: area V1**

Given the similar (though not identical) performance of macaque monkeys and humans on psychophysical tasks, it has often been assumed that macaque V1 must be functionally equivalent to human V1. However, there are a number of quantitative differences between the macaque and human visual system, which begin at the retina. For example, the dendritic fields of parasol ganglion cells are considerably larger in humans than in macaques, especially near the fovea, whereas human and macaque midget ganglion cells are more nearly similar [18]; also, human OFF midget retinal ganglion cells are smaller than their ON counterparts—a contrast not seen in the macaque retina [19]. A recent anatomical study demonstrated strongly correlated size variations in the optic tract, dorsal lateral geniculate nucleus (dLGN), and V1 within individual humans [20]. If successive stations in individual visual processing ‘streams’ show similar size correlations, these cross-species retinal differences may be correlated with, or even partly responsible for, cross-species differences in the relative sizes of cortical areas and within-area modules.

Some differences between human and macaque V1 have already been documented. For example, human ocular dominance stripes are larger than those in macaques, even after taking into account the larger size of human V1 [21]; therefore, humans have fewer stripes and fewer cytochrome oxidase blobs than macaques. Ocular dominance columns similar in size to those observed anatomically have recently been directly demonstrated with fMRI in the awake human V1 at 4 Tesla [22••]. The imaging of such small features bodes well for planned studies of modular structures in higher areas. The original report [13] of an increase in the cortical magnification factor near the center of gaze in human V1 relative to macaque V1 (after scaling by overall size) has been disputed because the blind spot in humans and macaques is at a similar proportional location in V1 (JC Horton, DR Hocking, *Soc Neurosci Abstr* 1997, 23:1945), and because it is difficult to extrapolate the exact center of gaze [16•]. The suggested increase in cortical magnification factor in the fovea at the expense of para-foveal locations, would, however, result in a similar placement of the blind spot. Higher-resolution stimuli, higher-resolution scans, and better eye movement control will be needed to resolve this issue.

Several fMRI studies have uncovered responses in V1 that were unexpected at this early cortical processing stage. A strong response to a boundary defined only by

a direction discontinuity in a field of moving random dots was demonstrated at the expected retinotopic position of the boundary in V1 [23•]. Another study showed that V1 responds much better to red–green contrast, and even to blue–yellow contrast, than it does to luminance contrast, suggesting a more widespread representation of color contrast in V1 than expected [24•].

#### **V4v and the inferior color and face areas**

A region of the posterior fusiform gyrus has been shown to be more responsive to right-side-up faces than to any other control object tried so far (e.g. houses, objects, hands and scrambled faces); the area responds to these other stimuli to some degree, but less strongly than to faces [25,26•]. The location of this area with respect to the ventroposterior area (VP [or V3v]) and ventral V4 (V4v) was unclear, however. By combining retinotopic mapping stimuli with face and object stimuli, the face-selective area was revealed to lie on the fusiform gyrus, just anterior to retinotopically defined V4v (E Halgren *et al.*, abstract in *Neuroimage* 1997, 5:S150). The inferior face-sensitive region does not adjoin V4v directly but is separated from it anteriorly by a distance approximately equal to the width of V4v.

Studies of brain-damaged humans have suggested that there is an inferior occipital color area that might be homologous to macaque V4v. One difficulty with this idea has been that retinotopically defined V4v in monkeys and humans [13,27] only contains a representation of the upper visual field, whereas most (but not all [28•]) reports of achromatopsia following inferior lesions have demonstrated involvement of lower as well as upper fields. A recent fMRI study explicitly demonstrated a selective response to a lower-visual-field isoluminant-colored stimulus in an inferior visual area near the location of retinotopically defined V4v [29•]. This study argued that the inferior displacement of the middle temporal (MT) area in humans relative to monkeys might explain why the newly revealed lower-field representation was so inferior. However, macaque V4d is situated between MT and the center-of-gaze representation of V1/V2. This region is still on the lateral surface in humans. An experiment combining visual mapping and isoluminant color stimuli in single subjects would resolve the issue. In monkeys, there is an area situated slightly anterior to the ventral upper-field representation of retinotopically organized V4v (VA) that receives input from both upper and lower visual fields in both macaque monkeys [27] and owl monkeys [30], but that is less well retinotopically organized than V4v.

#### **The organization of posterior superior occipital cortex (DM, DI, V3, V3A)**

The organization of the region of the cortex just anterior and superior to the center-of-gaze representation of V2 is complex and disputed (see Figure 1). I first consider work in nonhuman primates and then compare it with recent data from humans.

This region was mapped in detail in owl monkeys by Allman and Kaas [31], who found a heavily myelinated, dorsomedial (DM), area containing both lower and upper visual fields (mirror-image representation) directly apposed to lower field V2. They recognized another area containing an upper visual field, dorsointermediate area (DI), also directly in contact with V2, just lateral to DM. Zeki, Van Essen, Felleman and colleagues [32–34], by contrast, divided this region in macaques into two areas that were at right angles to the owl monkey areas. Posteriorly, a long thin area containing the lower visual field only, V3 (mirror image), adjoined much of the anterior border of lower field V2. V3 accessory area (V3A) was a more chunky area anterior to V3 (not touching V2), containing both lower and upper visual fields (existing reports do not specify the visual field sign of this area [33,35]). Krubitzer and Kaas [36] then argued that most of Old World monkey V3 and V3A could be combined into a single owl-monkey-like DM. Sereno *et al.* [10] described a DM in owl monkeys similar to that of Allman and Kaas (i.e. mirror image), but with an anterior-bending upper field and adjoined laterally by an area containing the upper visual field (DI) only, with the same visual field sign as V2 (non-mirror-image). The anterior border of this last area was marked by a (rare) discontinuity (see figure 8c in [10]); receptive fields jumped rapidly from the upper-field vertical meridian to the horizontal meridian upon entering the posterior subdivision of DL (DLp). Rosa and Schmid's [37] similarly detailed maps from marmoset monkeys have a mirror-image DM containing a visual field sign reversal in its lateral upper field representation (data similar to [10], though labeled differently). Ignoring the differences in nomenclature, a basic dichotomy has persisted—New World monkeys have sizeable upper visual field representations directly touching mid-dorsal V2 that have not been seen in the Old World macaque monkey.

A recent high-resolution mapping study of this region in humans presents a picture that appears similar to macaque V3 and V3A (lower-field-only V3 touching V2; lower-plus-upper V3A anterior to V3) [17••]. But, surprisingly, the motion-sensitive area turned out not to be V3 but the area just anterior to it. Human 'V3A' appears to be heavily myelinated (see area labeled 'possible/presumptive MT' figure 5 of [8] and figure 8 of [38]). In this respect, human V3A is similar to both owl monkey DM and macaque V3. The human area contains both upper and lower visual fields, similar to DM, but not V3; however, it also has a non-mirror-image representation, unlike either DM or V3. Higher resolution scans will be required to determine whether or not there are owl-monkey-like discontinuities in this region. An attempt to drive macaque V3A neurons with stimuli similar to those used in the human experiments was not successful (PX Joris, SE Raiguel, DK Xiao, GA Orban, *Soc Neurosci Abstr* 1997, 23:457). So for now, it seems that the areas

beyond superior V2 are simply more variable among different primate groups than the areas beyond inferior V2.

#### Other functions for visual cortex

The problem of defining to what extent higher cognitive functions engage visual areas is a difficult issue that will not be addressed in general here (see [39••,40]). It is nevertheless difficult to avoid mentioning several recent studies of visual cortex in blind people. In one study [41•], transcortical magnetic stimulation of occipital cortex was found to interfere with a Braille reading task in people blinded soon after birth, but not in sighted Braille readers, suggesting that early visual areas in blind people have been taken over for somatosensory tasks. A comparison between congenitally blind and subjects blinded later in life showed, however, that Braille-induced fMRI activations in early visual areas were only present in subjects with early visual experience (C Buchel, CJ Price, RSJ Frackowiak, KJ Friston, abstract in *Neuroimage* 1997, 5:S20). This lends some plausibility to the argument that noncongenitally blinded subjects may still be using their visual cortices years later for a kind of visual imagery.

#### Mapping other parts of the cortex

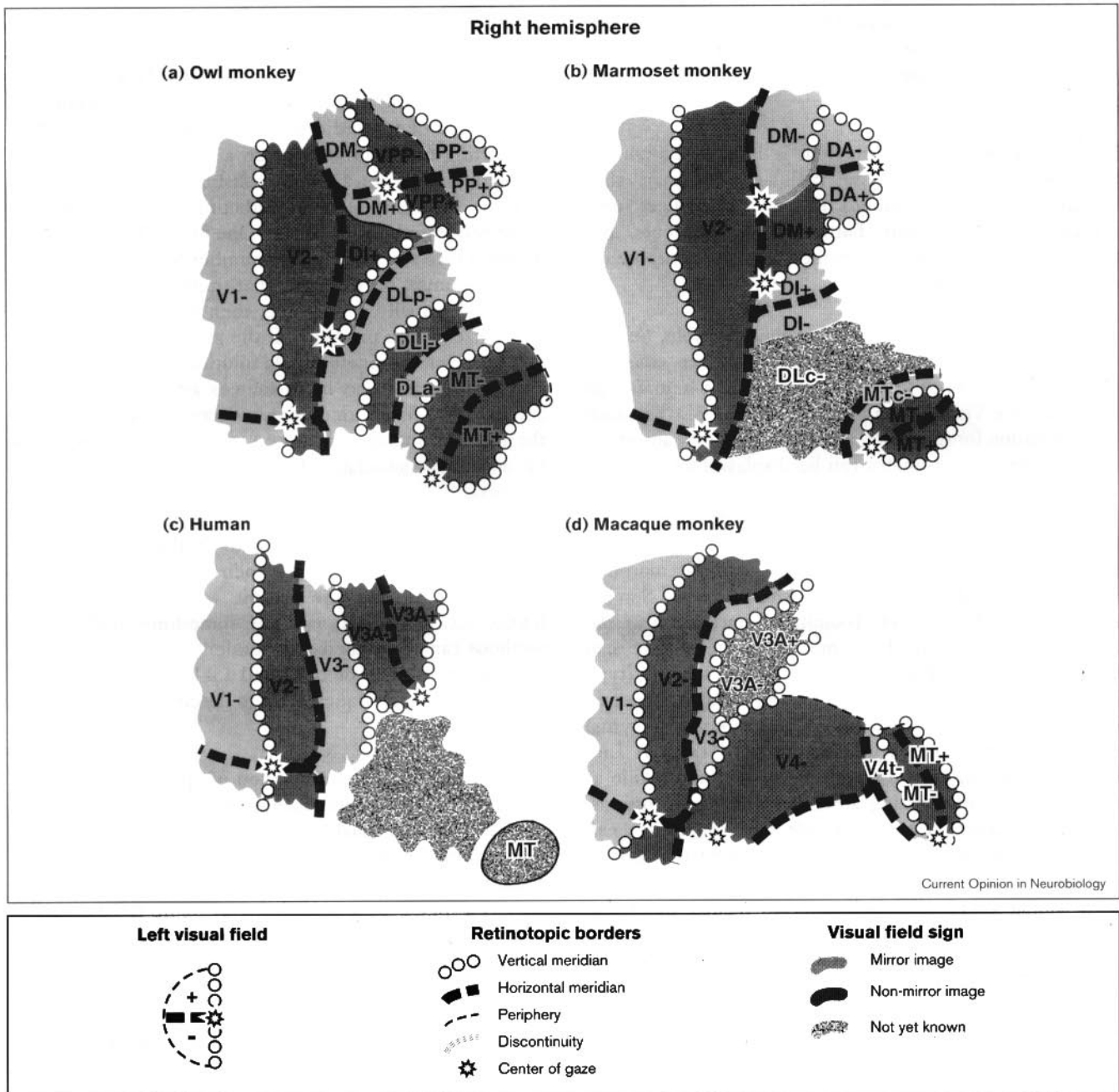
Phase-encoding mapping techniques have recently been applied to the auditory system (TM Talavage, PJ Ledden, MI Sereno, BR Rosen, AM Dale, abstract in *Neuroimage* 1997, 5:S8), revealing multiple maps of frequency similar to those found in other primates. The smaller size of auditory areas require more averaging; also, as there is only one dimension of frequency, other criteria must be used to identify borders perpendicular to isofrequency contours. Multiple motor areas [42] have also begun to be studied in humans [43•]. The recent demonstration that features can be represented continuously in higher visual areas [44], coupled with evidence for multiple spatial representations in parietal and premotor areas [45,46••], suggests that phase-encoded mapping strategies may be fruitfully extended beyond early sensory areas.

#### Surface-based data display and cross-subject averaging

Statistical activation maps of human brain imaging data are most commonly projected into the standardized Talairach three-dimensional (3D) space using a linear transformation (i.e. rotation, scaling, translation) and then viewed as a list of 3D foci, a set of 2D slices, an orthographic projection, or a solid 3D brain volume showing the surface location of the activations. These techniques can be automated [47] and have made it possible to routinely compare studies across subjects and laboratories.

There are obvious advantages, however, in being able to view anatomical and physiological data on the unfolded cortical surface. For example, many map features (e.g. magnification factor) can only be measured along the cortical surface. Surface-based methods are widely used in

Figure 1



Current understanding of the retinotopic organization of mid dorsal (superior) cortical visual areas in four primates. Visual areas in the right hemisphere, receiving input from the left visual field (see key at the bottom of the figure) are illustrated using standard symbols for retinotopy (circles for the visual field vertical meridian, dashes for the horizontal meridian, a star for the center-of-gaze, and plus (+) and minus (-) symbols for upper and lower visual fields). The wavy lines indicate a cortical map discontinuity, that is, nearby cortical points represent distant points in the visual field. This stands in contrast to the more familiar (and much more common) visual field discontinuities (e.g. at the anterior horizontal meridian border of V2), where nearby points in the visual field are represented at distant points on the cortex. **(a,b)** New World monkeys have areas (DM, DI) with upper visual fields (+) directly apposed to lower fields V2 (V2-), while the **(c)** humans and **(d)** Old World macaque monkeys have a single, lower-field-only area there (V3-). The cortical area in this region most sensitive to motion is lower-and-upper-field-containing DM in New World monkeys, lower-field-only V3 in Old World monkeys, but lower-and-upper-field 'V3A' in humans; thus, this region varies more between different primate species than does ventral (inferior) cortex (areas V2+, VP and V4v+). Cortical map discontinuities have not yet been reported here in humans and macaques, but the existing maps for these two species have a somewhat lower resolution due to cortical folding (macaques) and recording techniques (fMRI at 1.5 T). There are additional differences among primates anteriorly as one approaches MT/V5. New World owl monkeys, squirrel monkeys [57] and probably marmosets have three visual areas – DLP (DLc), DLI (DLr, not illustrated), DLa (MTc) – while this area in macaques is traditionally broken into only two areas – a very large V4d and a small V4t. Higher field (3 T) will be required to reveal the retinotopic organization of this area (and MT) in humans.

studies of the cortical organization in nonhuman primates [9]. They are even more useful in humans, in which the major sulci are obfuscated by numerous idiosyncratic secondary creases that make it particularly difficult to visualize the relative locations of activation foci given only slice data.

The cortex in an unfolded view is initially unfamiliar, but not harder to become familiar with than slice images. Unfolding ('inflating') the cortex introduces some distortion, and complete flattening requires cuts, but the original geometry is retained for the purpose of quantitative measurements.

Cortical-surface-based averaging is now possible. Several strategies have been demonstrated. A surface atlas has been generated for the two hemispheres of a human type specimen, the Visible Man [48\*\*]. Using the 3D Talairach transformation for this brain, activation foci from any study using Talairach coordinates can be displayed on it.

A higher-resolution brain-to-brain alignment can be obtained by using a surface-based approach. The reconstructed surface of each hemisphere can be morphed into a standard shape (e.g. an ellipsoid) (see MI Sereno, AM Dale, A Liu, RBH Tootell, abstract in *Neuroimage* 1996, 4:S352). At the same time, the surface can be stretched into alignment with a target brain (type specimen or average) by minimizing local differences in initial surface curvature (roughly sulcus versus gyrus) across the entire surface (MI Sereno, AM Dale, A Liu, RBH Tootell, *Soc Neurosci Abstr* 1996, 22:1060), while at the same time minimizing areal and angular distortions. A 2D coordinate system (latitude and longitude) can be applied before cutting. This parameterization of the unfolded cortex has the attractive property that points with similar coordinates will refer to nearby points on the cortical map—not generally true of a 3D coordinate system (nor of a Cartesian grid applied, as in [48\*\*], after cuts have been made).

There are a number of other more general methods for deforming an arbitrary 3D manifold into another (e.g. see [49,50]). These computationally intensive methods are likely to be especially useful for the more general problem of mapping brain structures not easily approximated by 2D surfaces.

### Combining imaging techniques

The blood oxygenation signal measured by standard fMRI has a rise time of several seconds. Several linear and nonlinear methods have recently been proposed to enable recording of event-related fMRI, reduction of temporal smearing, and correction of temporal overlaps [51,52\*\*,53]. Nevertheless, the connection with neural activity remains indirect. Magnetoencephalography (MEG) and electroencephalography (EEG), by contrast, are generated in large part by radial intracellular current flow in aligned arrays of

elongated apical dendrites of cortical pyramidal neurons [12]. As such, these methods provide a more intimate, millisecond-to-millisecond picture of cortical processing.

The primary drawback is that MEG/EEG source localization is difficult, and this difficulty varies non-uniformly with source depth and orientation. The forward problem (predicting the recordings given a set of sources) can be uniquely solved for a given realistic model of the head. But the inverse problem (predicting the set of sources given the recordings) is harder. One method of solving the problem is to set limits on the number of possible sources. If one assumes, for example, that there is only one dipole and there actually is only one, then it is usually possible to localize it with precision. If the assumed number is too low, however, the single-dipole solution will be misleading; on the other hand, as more sources are allowed (it takes about 10,000 fixed orientation sources to tile the cortex), the problem becomes ill posed (e.g. a deeper source can be accurately simulated by multiple smaller superficial sources).

fMRI and PET can be used to further constrain the inverse problem because of their uniform high spatial resolution. To test the extent to which fMRI and EEG/MEG actually do measure something similar, these methods can be applied independently to the same task. Preliminary studies of this kind [54] suggest that these very different techniques seem to detect activity in similar spatial locations.

To achieve the best combination of spatial and temporal resolution, however, the techniques can be combined to provide mutual formal constraints upon each other [55]. For example, a weighted linear inverse solution can be obtained by giving cortical locations with significant fMRI activity a higher prior probability of being EEG or MEG sources (but without completely preventing sites inactive in fMRI images from contributing to the solution) [12]. With this technique, it is essentially possible to extract the time course of activity of an fMRI site (AM Dale *et al.*, abstract in *Neuroimage* 1997, 5:S592). It is worth noting that this combination of techniques is not, in general, capable of specifically assigning activity to sources detected with fMRI that are close enough to each other to be indistinguishable by MEG and/or EEG alone (e.g. two neighboring visual areas). Nevertheless, the technique is excellently suited to detecting and localizing overlapping time courses of activity in motor, occipital, parietal and temporal cortices—which are far enough apart from each other.

### Conclusions

Recent brain mapping studies in humans have uncovered a set of early visual cortical areas with many similarities to early visual areas in New and Old World monkeys. Beyond V1, V2 and MT/V5, however, a number of differences have begun to emerge. Inferiorly, area VP is much larger

relative to V1 in humans than it is in macaques. It has been difficult to identify the putative superior counterpart of upper-visual-field-only V4v. There are several areas anterior to human V4v that are apparently specialized for processing complex learned visual stimuli such as faces and written words. Superiorly, a large V3 was uncovered (again, wider than expected from a macaque model). Quite surprisingly, it turned out not to be motion sensitive. The strongly motion-sensitive area was situated just anterior to V3, and contained both lower and upper visual fields.

A number of issues regarding the organization of visual areas remain. For example, visual inferotemporal cortex in monkeys extends virtually to the tip of the temporal lobe. Humans have more nonprimary cortex in the temporal lobe than monkeys and it remains to be seen whether humans have adapted higher visual areas to new tasks, or whether they have added a substantial set of new areas to the temporal lobe.

Methods for reconstructing, inflating and flattening the cortical surface more fully exploit the increased resolution provided by fMRI and are becoming easier to use. It is now possible to average surface-based data across subjects by warping surfaces into alignment with a type specimen or average target using the (former) location of major sulci. Several sites have begun to support web access to cortical-surface-based databases. Initial attempts to use fMRI to constrain electrical and magnetic source localization have been successful, and indicate that a combination of techniques will be capable of teasing out the time courses of overlapping activations of small groups of visual, somatosensory, auditory and motor areas.

## Acknowledgements

The author thanks Anders Dale, Eric Halgren, Roger Tootell, Bruce Fischl, Arthur Liu, Heather Drury, David Van Essen, Leah Krubitzer, Dan Felleman and Rosalyn Weller for discussions.

## References and recommended reading

Papers of particular interest, published within the annual period of review, have been highlighted as:

- of special interest
- of outstanding interest

1. Kay RF, Ross C, Williams BA: **Anthropoid origins.** *Science* 1997, **275**:797-804.
2. Krubitzer L: **The organization of neocortex in mammals: are species differences really so different?** *Trends Neurosci* 1995, **18**:408-417.
3. Kaas JF: **The evolution of isocortex.** *Brain Behav Evol* 1995, **46**:187-196.
4. Northcutt RG, Kaas JH: **The emergence and evolution of mammalian neocortex.** *Trends Neurosci* 1995, **18**:373-379.
5. Tootell RBH, Dale AM, Sereno MI, Malach R: **New images from human visual cortex.** *Trends Neurosci* 1996, **19**:481-489.
6. Courtney SM, Ungerleider LG: **What fMRI has taught us about human vision.** *Curr Opin Neurobiol* 1997, **7**:554-561.
7. Kaas JH, Krubitzer LA: **The organization of extrastriate visual cortex.** In *Neuroanatomy of Visual Pathways and Their Retinotopic Organization*, vol 3: *Vision and Visual Dysfunction*. Edited by Dreher B, Robinson SR. London: Macmillan; 1991:302-359.
8. Sereno MI, Allman JM: **Cortical visual areas in mammals.** In *The Neural Basis of Visual Function*. Edited by Leventhal A. London: Macmillan; 1991:160-172.
9. Felleman D, Van Essen DC: **Distributed hierarchical processing in primate visual cortex.** *Cereb Cortex* 1991, **1**:1-47.
10. Sereno MI, McDonald CT, Allman JM: **Analysis of retinotopic maps in extrastriate cortex.** *Cereb Cortex* 1994, **4**:601-620.
11. Engel SA, Rumelhart DE, Wandell BA, Lee AT, Glover GH, Chichilnisky EJ, Shadlen MN: **fMRI of human visual cortex.** *Nature* 1994, **369**:525.
12. Dale AM, Sereno MI: **Improved localization of cortical activity by combining EEG and MEG with MRI cortical surface reconstruction – a linear approach.** *J Cogn Neurosci* 1993, **5**:162-176.
13. Sereno MI, Dale AM, Reppas JB, Kwong KK, Belliveau JW, Brady TJ, Rosen BR, Tootell RBH: **Borders of multiple visual areas in human revealed by functional magnetic resonance imaging.** *Science* 1995, **268**:889-893.
14. Tootell RBH, Reppas JB, Dale AM, Look RB, Sereno MI, Malach R, Brady TJ, Rosen BR: **Visual motion aftereffect in human cortical area MT revealed by functional magnetic resonance imaging.** *Nature* 1995, **375**:139-141.
15. DeYoe EA, Carman GJ, Bandettini P, Glickman S, Wieser J, Cox R, Miller D, Neitz J: **Mapping striate and extrastriate visual areas in human cerebral cortex.** *Proc Natl Acad Sci USA* 1996, **93**:2382-2386.
16. Engel SA, Glover GH, Wandell BA: **Retinotopic organization in human visual cortex and the spatial precision of functional MRI.** *Cereb Cortex* 1997, **7**:181-192.
- This group used the continuously moving stimulus introduced by Engel *et al.* [11], and used by Sereno *et al.* [13] and Tootell *et al.* [17\*\*]. In this study, the authors mapped visual areas and estimated that the linespread function of the fMRI signal (full width at half maximum) is 3.5 mm. Their data on eccentricity as a function of cortical distance are very similar to those reported in Sereno *et al.* [13].
17. Tootell RBH, Mendola JD, Hadjikhani NK, Ledden PJ, Liu AK, Reppas JB, Sereno MI, Dale AM: **Functional analysis of V3A and related areas in human visual cortex.** *J Neurosci* 1997, **17**:7078-7088.
- Retinotopy in human visual cortex was analyzed with techniques similar to those in Sereno *et al.* [13], DeYoe *et al.* [15] and Engel *et al.* [16\*\*], but including thinner, impulse-like stimuli designed to reveal retinotopy in areas with larger receptive fields. A non-mirror-image area that contained both upper and lower visual fields was revealed anterior to superior, mirror-image V3. Although retinotopically similar to macaque V3 and V3A, the motion sensitivity of these two areas was transposed: V3 was not motion sensitive whereas V3A was.
18. Dacey DM, Petersen MR: **Dendritic field size and morphology of midget and parasol ganglion cells of the human retina.** *Proc Natl Acad Sci USA* 1992, **89**:9666-9670.
19. Dacey DM: **The mosaic of midget ganglion cells in the human retina.** *J Neurosci* 1993, **13**:5334-5355.
20. Andrews TJ, Halpern SD, Purves D: **Correlated size variations in human visual cortex, lateral geniculate nucleus, and optic tract.** *J Neurosci* 1997, **17**:2859-2868.
21. Horton JH, Stryker MP: **Amblyopia induced by anisometropia without shrinkage of ocular dominance columns in human striate cortex.** *Proc Natl Acad Sci USA* 1993, **90**:5495-5498.
22. Menon RS, Ogawa S, Strupp JP, Ugurbil K: **Ocular dominance in human V1 demonstrated by functional magnetic resonance imaging.** *J Neurophysiol* 1997, **77**:2780-2787.
- Human ocular dominance columns with a width (~1 mm) comparable to that reported in Horton and Stryker [21] were demonstrated using a 4 Tesla magnetic field and stimuli flashed alternately in the left and right eyes. Four 4 mm slices parallel to the calcarine sulcus with an in-plane resolution of about 0.5 mm were used. This study was the first to demonstrate convincingly selective activation of individual cortical columns.
23. Reppas JB, Niyogi S, Dale AM, Sereno MI, Tootell RBH: **Motion segmentation in retinotopic areas of the human visual cortex.** *Nature* 1997, **388**:175-179.
- V1 responded in a retinotopic fashion to a border defined only by motion contrast. MT, by comparison, showed no difference in response to motion with borders and full-field motion.
24. Engel SA, Zhang X, Wandell BA: **Colour tuning in human visual cortex measured with functional magnetic resonance imaging.** *Nature* 1997, **388**:68-71.
- V1 and V2 were defined using retinotopic stimuli. A variety of single-cone stimuli were then used to investigate the extent to which human V1 responded to color contrast. V1 was several times more sensitive to red-green

contrast than to luminance contrast. The response to blue–yellow contrast was surprisingly strong, and even comparable to the luminance response.

25. Puce A, Allison T, Gore JC, McCarthy G: **Face-sensitive regions in human extrastriate cortex studied by functional MRI.** *J Neurophysiol* 1995, **74**:1192-1199.
  26. Kanwisher N, McDermott J, Chun MM: **The fusiform face area: a module in human extrastriate cortex specialized for face perception.** *J Neurosci* 1997, **17**:4302-4311.
- Responses to faces were compared with a number of other stimuli, including scrambled faces, houses and hands. The selective response to faces persisted despite the presence of a foil that also consisted of hard-to-distinguish stimuli from a single category.
27. Boussaoud D, Desimone R, Ungerleider LG: **Visual topography of area TEO in the macaque.** *J Comp Neurol* 1991, **306**:554-575.
  28. Merigan W, Freeman A, Meyers, SP: **Parallel processing streams in human visual cortex.** *Neuroreport* 1997, **8**:3985-3991.
- A patient suffered a small stroke in the left right fusiform gyrus that resulted in a severe disruption of color perception, shape discrimination and contrast sensitivity, which was restricted to the upper quadrant. This finding stands in contrast to many previous reports of achromatopsia, in which deficits extended into the lower visual field. The patient's motion perception was much less affected, supporting an independent visual streams view.
29. McKeefry DJ, Zeki S: **The position and topography of the human colour centre as revealed by functional magnetic resonance imaging.** *Brain* 1997, **120**:2229-2242.
- This paper demonstrates a response in inferior occipitotemporal cortex to an isoluminant color 'Mondrian' stimulus (relative to an achromatic version of the stimulus with luminance contrast) when the stimulus was restricted to both the upper visual field and the lower visual field. The lower field response suggests that this area lies beyond the lower-field-only V4v mapped by Sereno *et al.* [13] and Tootell *et al.* [17\*\*].
30. Weller RE, Kaas JH: **Subdivisions and connections of inferior temporal cortex in owl monkeys.** *J Comp Neurol* 1987, **256**:137-172.
  31. Allman JM, Kaas JH: **The dorsomedial cortical visual area: a third tier area in the occipital lobe of the owl monkey (*Aotus trivirgatus*).** *Brain Res* 1975, **100**:473-487.
  32. Van Essen DC, Zeki SM: **The topographic organization of rhesus monkey prestriate cortex.** *J Physiol* 1978, **277**:193-226.
  33. Van Essen DC, Felleman DJ, DeYoe EA, Olavarria J, Knierim J: **Modular and hierarchical organization of extrastriate visual cortex in the macaque monkey.** *Cold Spring Harb Symp Quant Biol* 1990, **55**:679-696.
  34. Felleman DJ, Burkhalter A, Van Essen DC: **Cortical connections of areas V3 and VP of macaque monkey extrastriate visual cortex.** *J Comp Neurol* 1997, **379**:21-47.
  35. Gattass R, Sousa APB, Gross CG: **Visuotopic organization and extent of V3 and V4 of the macaque.** *J Neurosci* 1988, **8**:1831-1845.
  36. Krubitzer LA, Kaas JH: **The dorsomedial visual area of owl monkeys: connections, myeloarchitecture, and homologies in other primates.** *J Comp Neurol* 1993, **334**:497-528.
  37. Rosa MGP, Schmid LM: **Visual areas in the dorsal and medial extrastriate cortices of the marmoset.** *J Comp Neurol* 1995, **359**:272-299.
  38. Tootell RBH, Taylor JB: **Anatomical evidence for MT and additional cortical visual areas in humans.** *Cereb Cortex* 1995, **5**:39-55.
  39. Frackowiak RSJ, Friston KJ, Frith CD, Dolan RJ, Mazziotta JC: **Human Brain Function.** San Diego: Academic Press; 1997.
- A wide-ranging, technical review of brain imaging techniques and results focusing on imaging studies (primarily PET) performed at the Hammersmith Hospital and University College, London, UK.
40. Binder JR, Frost JA, Hammeke TA, Cox RW, Rao SM, Prieto T: **Human brain language areas identified by functional magnetic resonance imaging.** *J Neurosci* 1997, **17**:353-362.
  41. Cohen LG, Celnik P, Pascual-Leone A, Corwell B, Falz L, Dambrosia J, Honda M, Sadato N, Gerloff C, Catala MD, Hallett M: **Functional relevance of cross-modal plasticity in blind humans.** *Nature* 1997, **389**:180-183.

Humans blind from an early age were compared to sighted people who also read Braille. Transcortical magnetic stimulation of occipital cortex in blind but not sighted people interfered with Braille reading. Surprisingly, occipital stimulation was more disruptive for blind subjects than stimulation near primary somatosensory cortex. These results demonstrate that early visual deprivation results in occipital cortex becoming intimately involved in processing somatosensory information.

42. Preuss TM, Stepniewska I, Jain N, Kaas JH: **Multiple divisions of macaque precentral motor cortex identified with neurofilament antibody SMI-32.** *Brain Res* 1997, **767**:148-153.
  43. Fink GR, Frackowiak RSJ, Pietrzyk U, Passingham RE: **Multiple nonprimary motor areas in the human cortex.** *J Neurophysiol* 1997, **77**:2164-2174.
- Subjects performed eyes-closed movements of their hand, shoulder or leg. This study provides single-subject PET evidence for three non-primary cingulate motor areas in humans similar to those studied previously in macaque monkeys by Strick and colleagues [56], as well as several lateral areas, one of which might be similar to macaque PMv.
44. Tanaka K: **Mechanisms of visual object recognition: monkey and human studies.** *Curr Opin Neurobiol* 1997, **7**:523-529.
  45. Rizzolatti G, Fogassi L, Gallese V: **Parietal cortex: from sight to action.** *Curr Opin Neurobiol* 1997, **7**:562-567.
  46. Duhamel JR, Bremner F, BenHamed S, Graf W: **Spatial invariance of visual receptive fields in parietal cortex neurons.** *Nature* 1997, **389**:845-848.
- The receptive fields of VIP neurons were mapped with brief moving stimuli while a macaque fixated different points on a screen. Its head was fixed. Some neurons exhibited head-centered receptive fields (as opposed to planar gain fields) – that is, the neuron's elliptical receptive field moved relative to the retina so that it was always aimed at the same position on the screen. Given that VIP has a crude topography, it may be possible to detect these coordinate transformations in human parietal cortex with high-resolution fMRI.
47. Collins DL, Neelin P, Peters TM, Evans AC: **Automatic 3D intersubject registration of MR volumetric data in standardized Talairach space.** *J Comp Assist Tomogr* 1994, **18**:192-205.
  48. Van Essen DC, Drury HA: **Structural and functional analysis of human cerebral cortex using a surface-based atlas.** *J Neurosci* 1997, **17**:7079-7102.
- Provides a complete reconstruction, flattening, and labeling of the two hemispheres of the Visible Man. The brain was transformed into the Talairach space and then 118 foci from 12 PET and fMRI studies were marked on it.
49. Miller M, Banerjee A, Christensen G, Joshi S, Khaneja N, Grenander U, Matejic L: **Statistical methods in computational anatomy.** *Stat Meth Med Res* 1997, **6**:267-299.
  50. Thompson PM, MacDonald D, Mega MS, Holmes CJ, Evans AC, Toga AW: **Detection and mapping of abnormal brain structure with a probabilistic atlas of cortical surfaces.** *J Comp Assist Tomogr* 1997, **21**:567-581.
  51. Boynton GM, Engel SA, Glover GH, Heeger DJ: **Linear systems analysis of functional magnetic resonance imaging in human V1.** *J Neurosci* 1996, **16**:4207-4221.
  52. Dale AM, Buckner RL: **Selective averaging of rapidly presented individual trials using fMRI.** *Hum Brain Map* 1997, **5**:329-340.
- This paper describes a simple, powerful method for selectively averaging rapidly presented individual trials with fMRI. By counter-balancing stimulus order and interstimulus interval jitter, it is possible to compare the response to different event classes by a simple timepoint-by-timepoint subtraction of the event-related waveforms, despite overlapping responses. Besides the greater flexibility in experimental design, this can be a more efficient way to collect data than a blocked design because the overlap results in more effective 'recording time' for each condition (each image/timepoint contributes to multiple trial types). Trials sorted post-hoc (e.g. by response), however, would have to be subjected to explicit overlap correction (G Ganis *et al.*, abstract in *Cogn Neurosci* 1997, 4:42).
53. Buckner RL, Bandettini PA, Ocraven KM, Savoy RL, Petersen SE, Raichle ME, Rosen BR: **Detection of cortical activation during averaged single trials of cognitive task using functional magnetic resonance imaging.** *Proc Natl Acad Sci USA* 1996, **93**:14878-14883.
  54. Heinze HJ, Mangun GR, Burchert W, Hinrichs H, Scholz M, Munte TF, Gos A, Scherg M, Johannes S, Hundeshagen H *et al.*: **Combined spatial and temporal imaging of brain activity during visual selective attention in humans.** *Nature* 1994, **372**:543-546.
  55. Barinaga M: **New imaging methods provide a better view into the brain.** *Science* 1997, **276**:1974-1976.
  56. Picard N, Strick PL: **Motor areas of the medial wall: a review of their location and functional activation.** *Cereb Cortex* 1996, **6**:342-353.
  57. Weller RE, Steele GE, Cusick CG: **Cortical connections of dorsal cortex rostral to V-II in squirrel monkeys.** *J Comp Neurol* 1991, **306**:521-537.